

Abnormality Detection and Its Severity Classification in Retinal Images

Archana.G¹, Avinaya.V², Chegireddy Keerthi³, Gayathri Shivaram⁴ and S.Vasanthi⁵

^{1,2,3,4} Electronics & Communication Engineering
K.S.Rangasamy College of Technology
Tiruchengode, India

⁵ Associate Professor, Electronics & Communication Engineering
K.S.Rangasamy College of Technology
Tiruchengode, India

Abstract

Diabetic Retinopathy (DR) is a major cause of blindness. Earliest signs of DR are damage to blood vessels in the eye and then the formation of lesions in the retina. This paper presents an automated method for the detection of bright lesions (exudates) in retinal images and its classification on the basis of their severity and level of risk. An exudate is any fluid that filters from the circulatory system into lesions or areas of inflammation. Its composition varies but generally includes water and the dissolved solutes of the main circulatory fluid such as sap or blood. Based on the amount of solutes it is classified as soft and hard exudates. Hard exudates are associated with DR and have been found to be one of the most prevalent earliest clinical signs of retinopathy. This proposal starts by eliminating the non-uniform illumination thereby enhancing the brightness of the images. A novel abnormality detection method is illustrated which classifies the retinal images as normal or abnormal based on the features obtained from the image. The abnormal images are further classified as mild, moderate or severe. The obtained results show effectiveness in both exudates detection and its severity classification in the field of diabetic retinopathy assessment.

Keywords: Diabetic Retinopathy (DR), hard exudates, soft exudates, detection and classification.

1. INTRODUCTION

Diabetic Retinopathy (DR) is a complication of diabetes that causes blindness to 2.2 million people in the world. It is a common cause of blindness especially in developed countries and

the risk of vision loss from DR increases when pathologies present on the macula are more. However, at an early stage an appropriate treatment slow down the progression of this disease. Thus, the recognition of the early signs has great importance in automatic screening systems. Exudates are primary signs of diabetic retinopathy and occur when lipid or fat leaks from blood vessels or aneurysms. Exudates are light, small spots, which can have irregular shape, thus automatic exudate detection is a difficult task.

Hard exudates are small white or yellowish white deposits with sharp margins. Often, they appear waxy, shiny, or glistening. They can be arranged as individual dots, confluent patches, sheets, or in rings or crescents surrounding zones of retinal edema or groups of microaneurysms. They are occasionally deposited along retinal veins. On angiography, small dots are not visible, but larger patches may block choroid fluorescence. Exudates are differentiated from drusen which hyper fluoresce during the transit phase and become less prominent in late phases. Microaneurysms that appear as white dots with no blood visible in the lumen are considered hard exudates. In extreme stages of Diabetic Retinopathy, certain spots called the 'cotton wool spots' are identified. The retinal pre capillary arterioles supplying blood to the nerve fiber layer are clogged and associatively the local nerve fiber axons get swollen; thereby creating a cotton wool spot (soft exudates). We can find a

large number of exudate detection algorithms in the medical image processing literature as see in [1].

In literature a very few work have been reported about the detection of exudates and it is observed that algorithms do not find all exudates and detect some false candidates. Several methods have already been implemented to segment the hard exudates. Harihar Narasimha-iyer *et al.* [1] estimated the illumination component using iterative robust homographic surface fitting to compensate the non-uniform illumination in fundus images for monitoring diabetic retinopathy. In detection of bright diabetic retinopathy areas from fundus images, Zhang and Chutape [2] applied adaptive local contrast enhancement to sub-image areas using the local mean and standard deviation of intensities. A similar approach for detection and classification of DR was used by Osareh *et al.* [3]. Other methods include fuzzy C means clustering [4], intensity based dynamic clustering [5], region growing segmentation [6-7], neural networks based classification [8-9], Gaussian Bayes classifier [10] and morphological closing techniques [11]. In the above mentioned methods the results were mostly classified as normal and abnormal.

This proposed method is an easier process which makes use of the pixel intensity of the exudates. The pixels that form exudates are extracted by removing all the unwanted features like blood vessels, Optic Disc (OD) and noise. Then based on the amount and intensity of the exudates the classification is done. Morphological approach has been used in this technique because with the use of region based approach, this accuracy cannot be attained. Also for attaining high sensitivity and specificity, clustering is done where the entire image is subdivided based on the intensity levels (gray scale image) of OD, blood vessels and exudates. Then the feature extraction is done and the final classification is done using Neuro Fuzzy C approach and finally the comparison of the morphological approach and clustering is done.

2. METHODOLOGY

The aim of the entire process is the detection of the abnormality in the fundus images with

respect to the exudates and their classification is done based on the area of the exudates. The fundus photographs of the exudates affected retina were collected from The Eye Foundation and Aravind Eye Hospital, Coimbatore. They were captured using high resolution fundus camera. The normal fundus photographs, taken for the diagnostic processes contain noise. If the detection is made with those same images it may lead to malicious results. Hence to improve the image quality, uneven illumination, insufficient contrast between the exudates and the image background pixels and to remove the noises present in the input fundus images we go for the preprocessing step initially. This stage involves a number of steps like resizing the image, gray conversion, date patch removal and brightness adjustment. Initially the fundus image is standardized to 576x720 and the intensity of the gray scale image is then adjusted.

Once the preprocessing is successfully completed, the circular border of the image is detected using edge detection algorithm. Then the blood vessels are removed from the input image. In the same manner we remove the OD and noise from the input gray image independently. Then the logical AND operation of the original image and the image in which the optical disc, noise and blood vessels have been removed is done.

After the AND operation has been performed the final image is obtained which consists of exudates alone. Then the image is analyzed which consists of exudates alone and further we calculate the region of interest i.e. where the exudates are present in the image. Based on this, the classification of exudates is done as normal, mild, severe and proliferative.

The main objective of the proposed project is to identify the defective part on the retina of eye caused due to Exudates. For this purpose, an image (Fig.1) is chosen that has been affected by Exudates using a fundus camera which is depicted above. This image consists of optic disk (OD), blood vessels and exudates.

$$(A \oplus B)(x, y) = \max\{A(x - x', y - y') \mid (x', y') \in D_B\} \quad (1)$$

Equation 1 is used for the dilation process during the conversion of RGB image into gray.

$$A \oplus B = \{z | (\hat{B})_z \cap A \neq \phi\}$$

The binary erosion is done in the process of removing the blood vessels and is depicted in the equation 2.

For the purpose of processing the input fundus image in a better and easier manner, the RGB image is converted into Gray scale image (Fig.2) using operation, which replaces the original red, green and blue values with the new gray value. This helps to identify all the exudates, optic disc and blood vessels clearly.

Since the major focus is only on the region of exudates, the blood vessels in the image are not of much importance. Thus in this stage the blood vessels from the gray scale image have been removed (Fig.3). For doing this we do morphological operation. In this a ball shape is chosen which concentrates on the circular eye and then the blood vessel region which is unclosed is closed automatically.

$$\eta(x) = \begin{cases} x & |x| \geq T \\ 0 & |x| < T \end{cases} \neq \phi \quad (3)$$

For the process of thresholding the gray values to binary, we use the technique called soft thresholding whose algorithm is depicted by the equation 3.

The processing has to be done only in the region of interest of the image, thus the circular border (Fig.4) that comprises the portions of retina of the eye alone is detected. In order to detect the circular edge of the eye, the edge detection technique is used. This technique takes a gray scale or a binary image I as its input, and returns a binary image BW of the same size as I, with 1's where the function finds edges in I and 0's elsewhere.

The Canny method finds edges by looking for local maxima of the gradient of I. The gradient is calculated using the derivative of a Gaussian filter. The method uses two thresholds, to detect strong and weak edges, and includes the weak edges in the output only if they are connected to strong edges. This method is therefore less likely

than the others to be fooled by noise, and more likely to detect true weak edges.

(2)
 The mask for removing the optic disc has been shown in Fig.5. In this algorithm the size of the OD is chosen to be equal to 90. As the size of the OD is not constant for all the retinas, the worst case is taken into consideration so that if the OD is not misinterpreted as exudates as both of them have the same intensity levels.

Then the OD is removed as its brightness and intensity values are almost equal to that of the exudates. A circular mask of uniform brightness is used to do this process. Here the circular mask is made to move from the top to bottom pixel by pixel. When this is done, if this mask encounters a same surface (OD), the mask will fix onto that and when we perform logical operation on the gray image and this image, the optic disc is removed. Thus the Fig.6 depicts only the region affected by exudates. After the removal of the optic disc, the only dominant high intensity features are the exudates which are efficiently separated and shown in Fig.6.

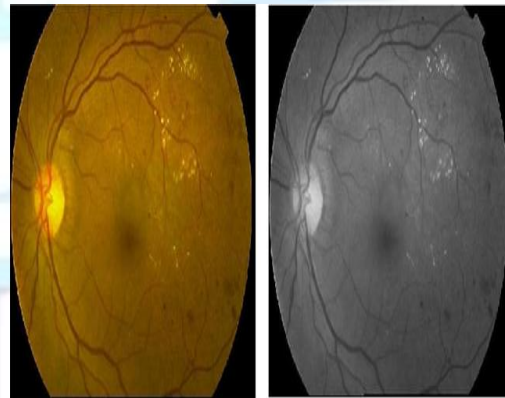


FIGURE 1: Input Retinal image
 FIGURE 2: Gray Scale image




FIGURE 3: Blood vessels removed image




FIGURE 4: Circular Border




FIGURE 5: Mask for optic disk removal

FIGURE 6: Image with Exudates alone

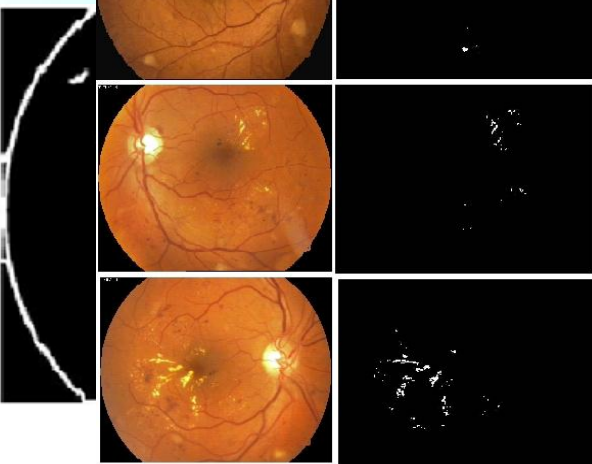


FIGURE 7: Input Retinal images and their corresponding exudate detected image for various stages

3. EXPERIMENTAL RESULTS

A set of 50 images captured under standard protocols obtained from eye care centers and diabetic retinopathy databases [14] were used for analysis. The algorithm was tested using the training sample. The accuracy of the classifier depends on better segmentation and brightness levels of the exudates and also on accurately extracting the parameters used for classification. The physical features like shape and size of the spots were comparable to the ground truth. The Fig.7 shows the comparison between the ground truths and the segmentation by the proposed method for mild, moderate, severe and proliferative cases. The first set shows the segmentation results of an image that has mild diabetic retinopathy and is characterized by fewer exudates with less intensity. The second set shows the segmentation results of an image that has moderate level of severity and is

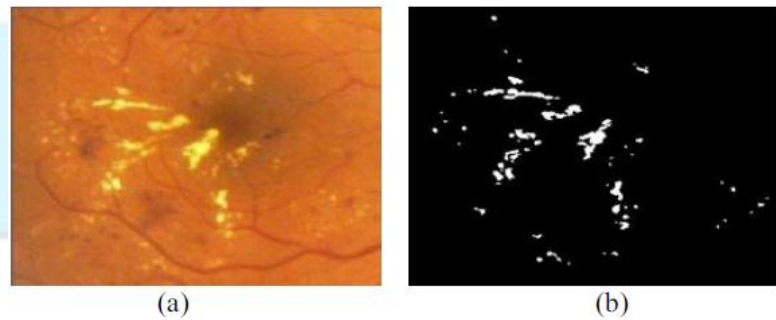


FIGURE 8: (a) Cropped retinal image (b) Ground truth image (c) Exudates segmented by proposed method

4. CONCLUSION

In this work, the detection and classification of exudates in retinal fundus images was carried out. The segmentation performed using

brightness associative criterion results in high sensitivity, specificity and accuracy as they matched better with the ground truth images. The proposed method is simple and easier to implement when compared to conventional methods as it involves only logical operations on the RGB channels of the image. The error-boost feature selection method effectively identifies the weak classifiers. The classifier predicts the severity of DR based on the two strongest features, more accurately. The proposed procedure seems to be useful for severity grading, mass screening and also for clinical interventions.

5. REFERENCES

- [1] K. Sai Deepak and Jayanthi Sivaswamy, Member, IEEE "Automatic assessment of macular edema from color retinal images" *IEEE Transactions on Medical Imaging*, vol.31, no. 3, pp. 766-776, march 2012.
- [2] Carla Agurto, Honggang Yu, Victor Murray, Marios S.Pattichis, Simon Barriga, Peter Soliz, Member, IEEE "Detection of hard exudates and red lesions in the macula using a multiscale approach" Published on *SSIAI*, pp.13-16, 2012.
- [3] A.V.Pradeep Kumar, C.Prashanth, G.Kavitha, Member, IEEE "Segmentation and grading of diabetic retinopathic exudates using error-boost feature selection method" *Transactions on 2011 World Congress on Information and Communication Technologies*, pp.518-523, 2011.
- [4] L. Giancardo, F. Meriaudeau, T.P. Karnowskit Y. Li. W.Tobin Jr. t E. Chaum, MD University of Burgundy Oak: Ridge National Laboratory "Automatic retina exudates segmentation without a manually labelled training set" *ISBI 2011*, IEEE, pp.1396-1400, 2011.
- [5] Brigitta Nagy, Debrecen, Hungary, Balint Antal, Andras Hajdu, Balazs Harangi, Faculty of Informatics, University of Debrecen, Hungary, "Ensemble-based exudate detection in color fundus Images", *7th International Symposium on Image and Signal Processing and Analysis (ISPA 2011)*, pp.700-703, September 4-6, 2011.
- [6] Hussain F. Jaafar, Asoke K. Nandi, and Waleed Al-Nuaimy, Member, IEEE "Detection of exudates in retinal images using a pure splitting technique" *32nd Annual International Conference of the IEEE EMBS*, pp.6745-6748, Buenos Aires, Argentina, August 31 - September 4, 2010.
- [7] Carla Agurto, Victor Murray, Eduardo Barriga, Sergio Murillo, Marios Pattichis, Herbert Davis, Stephen Russell, Member, IEEE "Multiscale AM-FM methods for diabetic retinopathy lesion detection" *IEEE Transactions on Medical Imaging*, Vol. 29, No. 2, pp.502-511, February 2010.
- [8] Alireza Osareh, Bitra Shadgar and Richard Markham, Member, IEEE "A computational-intelligence-based approach for detection of exudates in diabetic retinopathy images" *IEEE Transactions On Information Technology In Biomedicine*, Vol. 13, No. 4, pp.535-545, July 2009.
- [9] Clara I. Sánchez, Agustin Mayo, Maria Garcia, Maria I. Lopez and Roberto Hornero, Member, IEEE "Automatic image processing algorithm to detect hard exudates based on mixture models" *Proceedings of the 28th IEEE EMBS*, pp.4453-4456 Annual International Conference New York City, USA, Aug 30-Sept 3, 2006.
- [10] Thomas Walter, Jean-Claude Klein, Pascale Massin, and Ali Erginay, "A contribution of image processing to the diagnosis of diabetic retinopathy—detection of exudates in color fundus images of the human retina", *IEEE Transactions On Medical Imaging*, Vol. 21, No. 10, pp. 1236- 1243, October 2002.
- [11] Meindert Niemeijer, Bram van Ginneken, Stephen R. Russell, Maria S. A. Suttorp - Schulten, Michael D. Abramoff, "Automated detection and differentiation of drusen, exudates, and cotton-wool spots in digital color fundus photographs for diabetic retinopathy diagnosis", *Investigative Ophthalmology and Visual Science*, Vol.48, pp.2260-2267, 2007.
- [12] Akara Sopharaka, Bunyarit Uyyanonvaraa, Sarah Barmanb, Thomas H. Williamsonc, "Automatic detection of diabetic retinopathy exudates from non-dilated retinal images using mathematical morphology methods", *Computerized Medical Imaging and Graphics*, Vol. 32, No. 8, pp.720-727, 2008.
- [13] Ahmed Wasif Reza, C. Eswaran, Subhas Hati, "Automatic tracing of optic disc and exudates from color fundus images using fixed and variable thresholds", *Journal of Medical Systems*, Vol. 33, No. 1, pp. 73-80, February 2009.
- [14] T. Kauppi, V. Kalesnykiene, J.-K. Kamarainen, L. Lensu, I. Sorri, H. Kalviainen, and J. Pietila, "Diaretdb1 diabetic retinopathy database and evaluation protocol", in *Proc. 11th Conf. on Medical Image Understanding and Analysis*, 2007.